

Fișa suspiciunii de plagiat / Sheet of plagiarism's suspicion	Indexat la: 19/07
--	------------------------------

Opera suspicionată (OS)	Opera autentică (OA)
Suspicious work	Authentic work

OS	IVĂNESCU, A., MELINTE, R., SOLYOM, A., MORARU, L., PETRIȘOR, M. and Brânzaniuc, Klara, "Transchondral drilling and osteochondral autograft (Mosaicoplasty) in knee articular cartilage defects", <i>Acta Medica Marisiensis</i> , Vol. 57, No.4, p.303-305, 2011.
OA	KARATAGLIS, D., GREEN, M.S., and LEARMONTH, D.J.A., Autologous osteochondral transplantation for the treatment of chondral defects of the knee, <i>The Knee</i> , No.13, p.32-35, 2006.

Incidența minimă a suspiciunii / Minimum incidence of suspicion	
p.304: 25s – p.304:40s;	p.33: 14s – p.33:40s
p.304: 06d – p.304:31d	p.33: 06d – p.33:38d
p.305: 04s – p.305:23s	p.34: 01s – p.34:19s
Fișa întocmită pentru includerea suspiciunii în Indexul Operelor Plagiate în România de la www.plagiate.ro	

Documente care se referă la faptele de plagiat probate:

A¹.

Consiliul Național de Etică a Cercetării Științifice, Dezvoltării Tehnologice și Inovării (CNECSDTI) a înregistrat cu nr. 255/9.03.2012 adresa cu nr. 8304/6.03.2012 trimisă de Ministerul Educației, Cercetării, Tineretului și Sportului (MECTS), Direcția Generală de Învățământ Superior.

În această adresă se solicită soluționarea memoriilor înregistrate la MECTS cu nr. 8304 / 13.02.2012 și nr. 8304bis/21.02.2012, cu privire la posibile abateri grave de la buna conduită în cercetarea științifică și activitatea universitară. În sesizarea cu nr. 8304 / 6.03.2012 adresată Ministrului Educației, Cercetării, Tineretului și Sportului, reclamantul dorește „să atragă atenția asupra actelor de plagiat ale rectorului Copotoiu, ale prorectorului Brânzaniuc și ale decanului Azamfirei de la Universitatea de Medicină și Farmacie Târgu Mureș”.

Reclamantul afirmă că persoanele reclamate sunt coautori la articole plagiate și aduce în sprijinul afirmațiilor sale declarațiile autorilor lucrărilor presupus a fi plagiate.....

... Prin urmare, CNECSDTI constată că autorii A. Ivănescu, R. Melinte, A. Solyom, L. Moraru, M. Petrisor și K. Brânzaniuc au expus într-o operă scrisă texte, expresii și idei extrase dintr-o altă operă scrisă, fără a menționa acest lucru și fără a face trimitere la sursele originale. Având în vedere prevederile articolului 2, litera a), și articolului 4, alineatul (1), litera d) din Legea 206/2004 cu modificările și completările ulterioare, CNECSDTI constată că semnatarii articolului incriminat se fac vinovați de abaterea de la normele de bună conduită în activitatea de cercetare privind articolul Hayan R., Gicquel P., Schneider L., Karger C., Clavert J.M., Juvenile osteochondritis of femoral condyles: treatment with transchondral drilling. *Analysis of 40 cases*, din: *J Child Orthop*, No. 4, 2010, pp. 39-44 și articolul D. Karataglis, M.A. Green, D.J.A. Learmonth, Autologous osteochondral transplantation for the treatment of chondral defects of the knee, din *The Knee* 13 (2006), pp. 32-35.

¹ Consiliul Național de Etică a Cercetării Științifice, Dezvoltării Tehnologice și Inovării. Raportul final nr.977/ 26.09.2012. Disponibil la: <http://cne.ancs.ro/wp-content/uploads/2012/11/Raportul-final-nr.-977.pdf>

CNCSDTI constată că a fost publicată o erată la acest articol A2 în Acta Medici Marisiensis 2011, 57(4): 383 — 385.

Pentru articolul A3: The presence of Nucleated Red Cells in the Blood of Critical Care Patients is Associated with an Increased Mortality Risk, autori: Duțu M., Negoită S., Manolescu R., Calu V., Corneci D., Georgescu A., Togănel C., Azamfirei L. a fost analizat de către Comisia de Etică a UMF Târgu Mureș la data de 17.09.2012,

CNCSDTI constată că a fost publicată o erată la acest articol A3 în Acta medici Marisiensis 2022, 58(2): 132.

În concluzie, CNECSDTI constată că lucrările:

A1. Immunohistochemical Evaluation of Sentinel Lymph Nodes in Colon Cancer, autori: Șorlea S., Coros M.F., Georgescu R., Gyrgy-Fazakas I., Brânzaniuc K., Milutin D., Pavai Z., Copotoiu C.

A2. Transchondral drilling and osteochondral autograft (Mosaicplasty) inknee articular cartilage defects, autori: Ivănescu A., Melinte R., Solyom A., Moraru L., Petrisor M., Brânzaniuc K.

A3. The presence of Nucleated Red Cells in the Blood of Critical Care Patients is Associated with an Increased Mortality Risk, autori Duțu M., Negoita S., Manolescu R., Calu V., Corneci D., Georgescu A., Toganel C., Azamfirei L., nu respectă normele de bună conduită în activitatea de comunicare, publicare diseminare și popularizare științifică.

S. Șorlea nu a respectat normele de bună conduită în cercetare prin includerea în lista de autori a unei publicații științifice a două persoane fără acordul acestora. A fost sancționat de Comisia de Etică a UMF Târgu Mureș cu suspendarea, pe o perioadă de 12 luni, a dreptului de înscriere la un concurs pentru ocuparea unei funcții didactice superioare ori a unei funcții de conducere, de îndrumare și de control, ca membru în orice comisie de doctorat, de master sau de licență, sancțiune regăsită.

A. Ivănescu nu a respectat aceleași norme de bună conduită în cercetare incluzând trei persoane fără acordul acestora pe lista de autori a unei publicații științifice. A fost sancționat de Comisia de Etică a UMF Târgu Mureș cu avertisment scris.

Dr. Duțu M. nu a respectat normele de bună conduită în cercetare prin includerea prof. L. Azamfirei ca ultim autor al articolului A3 fără acordul acestuia. A fost sancționată de Comisia de Etică a UMF Târgu Mureș cu avertisment scris.

Prof. C. Copotoiu și prof. K. Brânzaniuc nu pot fi făcuți responsabili de nerespectarea normelor de bună conduită în cercetare din articolul A1, întrucât nu li s-a cerut acordul de a face parte din lista de autori.

Prof. Azamfirei L. nu poate fi făcut responsabil de nerespectarea normelor de bună conduită din articolul A3, întrucât nu i s-a cerut acordul de a face parte din lista de autori.

4) Sancțiuni și recomandări

4.1. CNECSDTI stabilește următoarele sancțiuni:

Avertisment scris, în baza Legii 206/2004 cu modificările și completările ulterioare, art. 14, alin.(1), lit. a), coroborat cu Legea 1/2011, art. 324, litera a) pentru doamna prof dr. K. Bânzaniuc.

...

Autologous osteochondral transplantation for the treatment of chondral defects of the knee

D. Karataglis, M.A. Green, D.J.A. Learmonth *

Royal Orthopaedic Hospital, Bristol Road South, Birmingham B31 2AP, UK

Received 1 December 2004; accepted 26 May 2005

Abstract

Full-thickness chondral defects of weight-bearing articular surfaces of the knee are a difficult condition to treat. Our aim is to evaluate the mid- and long-term functional outcome of the treatment of osteochondral defects of the knee with autologous osteochondral transplantation with the OATS technique. Thirty-six patients (37 procedures) were included in this study. Twenty-three patients were male and thirteen were female with a mean age of 31.9 years (range: 18–48 years). The cause of the defect was OCD in 10 cases, AVN in 2, lateral patellar maltracking in 7, while in the remaining 17 patients the defect was post-traumatic. The lesion was located on the femoral condyles in 26 cases and the patellofemoral joint in the remaining 11. The average area covered was 2.73 cm² (range: 0.8–12 cm²) and patients were followed for an average of 36.9 months (range: 18–73 months).

The average score in their Tegner Activity Scale was 3.76 (range: 1–8), while their score in Activities of Daily Living Scale of the Knee Outcome Survey ranged from 18 to 98 with an average of 72.3. Thirty-two out of 37 patients (86.5%) reported improvement of their pre-operative symptoms. All but 5 patients returned to their previous occupation while 18 went back to sports. No correlation was found between patient age at operation, the size or site of the chondral lesion and the functional outcome.

We believe that autologous osteochondral grafting with the OATS technique is a safe and successful treatment option for focal osteochondral defects of the knee. It offers a very satisfactory functional outcome and does not compromise the patient's future options.

© 2005 Published by Elsevier B.V.

Keywords: Osteochondral transplantation; Chondral defect; Knee; Arthroscopy

1. Introduction

The management of full-thickness chondral defects of a weight-bearing articular surface remains a contentious issue. The repair capacity of articular cartilage is limited, especially in large defects occurring after skeletal maturity [1–5]. Spontaneous repair as well as resurfacing promoted by treatment options such as abrasion arthroplasty, microfractures and drilling occurs with the formation of reparative fibrocartilage, has poor biomechanical characteristics compared to hyaline cartilage [2,5].

Osteochondral autograft transplantation is a method, which provides autologous hyaline cartilage for resurfacing

the chondral defect, thus reconstructing more accurately both the histological and biomechanical properties of the articular surface [6–11]. It has, though, technical limitations, mainly related to the size of the defect and to donor site morbidity [12].

Our aim was to evaluate the mid- and long-term functional outcome of the treatment of osteochondral defects of the knee joint with autologous osteochondral transplantation with the OATS technique.

2. Materials and methods

Between July 1998 and March 2003, 42 patients underwent 43 procedures for autologous osteochondral transplantation (one bilateral) with the OATS technique (Osteochondral Autograft Transplantation System, Arthrex, Naples, USA). Six patients were

* Corresponding author. Tel.: +44 121 685 4161.

E-mail addresses: dkarataglis@yahoo.gr (D. Karataglis), djal.scope@virgin.net (D.J.A. Learmonth).

not available on final follow-up, and therefore, 36 patients (37 procedures) were included in this study. Of those patients, 23 were male and 13 were female with a mean age of 31.9 years (range: 18–48 years). The cause of the chondral defect was osteochondritis dissecans (OCD) in 10 cases, avascular necrosis (AVN) in 2, lateral patellar maltracking in 7, while in the remaining 17 patients, the defect was post-traumatic following a road traffic accident, fall from a height or a sporting injury. The lesion was located on the medial femoral condyle in 18 cases, on the lateral femoral condyle in 8, on the trochlea in 7 and on the patella in the remaining 4.

The joint was initially assessed arthroscopically and the defect size, as well as the extent of subchondral bone loss was recorded (Fig. 1). Subsequently autologous osteochondral transplantation was carried out with the OATS technique (Osteochondral Autograft Transplantation System, Arthrex, Naples, USA), which allows for press-fit graft implantation (Fig. 2). Grafts were harvested from the lateral or medial edge of the trochlea and secondarily from the notch if more graft was required. The depth of the donor osteochondral plug ranged from 12 to 15 mm and the recipient site was drilled to such a depth so as to compensate for any potential subchondral bone loss and at the same time allow for some bone impaction. Care was taken to achieve perpendicular graft insertion, deliver the graft flush with the joint surface and reproduce the joint curvature as close to anatomical as possible. In 22 cases, graft harvesting and subsequent implantation was carried out following an arthrotomy, while in the remaining 15 cases, grafts were harvested through a mini-arthrotomy and implanted arthroscopically. In two patients where the lesion size was 12 cm² and 6.7 cm², respectively, a combination of autograft and allograft material was used due to the size of the defect.

A drain was inserted in the joint for 24 hours and patients were encouraged to start passive mobilisation of their knee as soon as pain allowed. Touch-toe weight bearing was advocated for 4–6 weeks and patients gradually progressed to full weight-bearing thereafter. Patients who underwent osteochondral transplantation to the articular surface of the trochlea or the patella had their knee immobilised in extension for 3–4 weeks in order to protect the graft.

Osteochondral transplantation was combined with ACL reconstruction in 4 cases, lateral meniscal repair in 1 and a

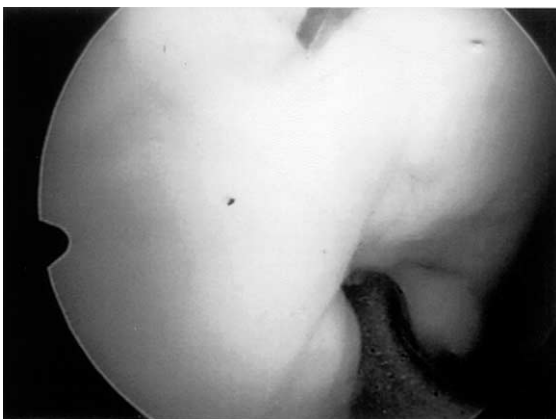

Fig. 1. Osteochondral lesion of the medial femoral condyle in a 35-year-old patient.

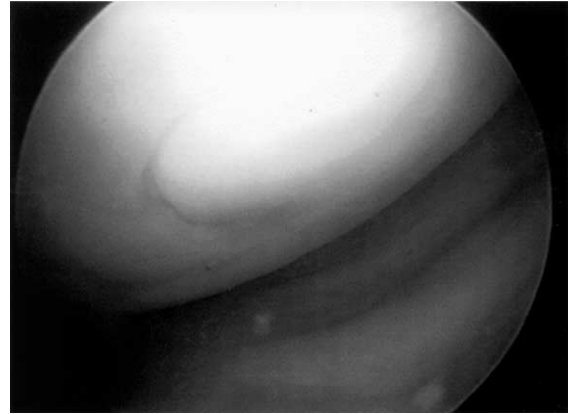


Fig. 2. Following treatment with autologous osteochondral transplantation covering of the defect with hyaline cartilage and satisfactory graft incorporation is seen during second look arthroscopy.

lateral release or an Elmslie–Trillat procedure in all 7 cases with an element of lateral patellar maltracking. Functional evaluation was performed using questionnaires using the Tegner activity scale and the Activities of Daily Living Scale of the Knee Outcome Survey [13].

3. Results

2

The average area of the osteochondral lesion covered with autologous osteochondral transplantation ranged from 0.8 to 12 cm² (average: 2.73 cm²). The diameter of the grafts used ranged from 6 to 10 mm and 1 to 8 grafts were used in each case to achieve > 90% covering of the lesion area. Patients were hospitalised for an average period of 3.06 days (range 1–6 days).

Patients were followed for a minimum of 18 months (average: 36.9 months, range: 18–73 months). The average score in their Tegner Activity Scale was 3.76 (range: 1–8), while their score in Activities of Daily Living Scale of the Knee Outcome Survey ranged from 18 to 98 with an average of 72.3. Thirty-two out of thirty-seven patients (86.5%) reported improvement of their pre-operative symptoms. All but 5 returned to their previous occupation and regular day-to-day activities and 18 went back to sports. No correlation was found between patient age at operation, the size or site of the chondral lesion and the functional outcome as depicted in the outcome measures used.

Nine patients had a second look arthroscopy for ongoing swelling, pain or clicking 7–13 months following their initial procedure. Arthroscopic assessment was combined with arthrolysis in one case, debridement and chondroplasty around the graft in four cases and partial medial meniscectomy in a further two cases. The grafts were found to be stable, well incorporated and with satisfactory chondrocyte survival in all but two cases, where they were loose and were therefore revised. In four out of those nine patients, symptoms improved significantly.

No donor-site related morbidity was recorded. One patient had a superficial wound infection that was successfully managed with oral antibiotics and one had a deep vein thrombosis and was warfarinised.

4. Discussion

3

Osteochondral defects spontaneously heal with fibrocartilage and treatment options such as abrasion arthroplasty, microfractures and drilling also promote the formation of fibrocartilaginous tissue, whose load-bearing properties and histological characteristics are significantly inferior to those of normal hyaline cartilage [2,14–16]. Furthermore, fibrocartilage has been shown to fibrillate and degrade with time, resulting in further deterioration of its loading characteristics [17]. In weight-bearing areas of the knee, this can cause impairment of smooth load transmission, leading to point loading and thus predisposing to development of osteoarthritis.

It is only osteochondral transplantation and autologous chondrocyte implantation that can provide hyaline cartilage covering of the articular surface defect. Autologous chondrocyte implantation leads to covering of the defect with predominantly hyaline or hyaline-like cartilage [18], although this has been challenged by recent reports [19].

Cost, as well as the need for two operative procedures, in order to initially harvest cartilage, culture it and subsequently implant it during a second procedure a few weeks later, remain concerns regarding this method. The functional outcome with autologous chondrocyte implantation is satisfactory, but it is a matter of debate if it is superior to autologous osteochondral transplantation [18,19].

Autologous osteochondral transplantation, on the other hand, is an appealing option, as it allows for coverage of the chondral lesion with adequate thickness, good quality hyaline cartilage and at the same time closely reproduces the anatomical condyle curvature [20–23]. Stabilisation of the grafts in the recipient area with a press-fit technique allows for satisfactory initial graft stability and obviates the need for any sort of internal fixation. A high rate of successful graft incorporation is subsequently achieved through direct bone healing in the surface between the graft and the recipient area. A number of authors have reported a high rate of symptom relief and functional improvement, as well as very satisfactory survival of the transplanted hyaline cartilage [6–11,24–27]. This method, though, has certain limitations, namely, increased donor site morbidity and a less favourable outcome when used for relatively sizeable defects ($> 2 \times 2$ cm) [12,28].

3

Cadaveric studies have demonstrated that grafts harvested from the lateral or medial edge of the trochlea can better reproduce the anatomical curvature of the recipient sites on the femoral condyle [22,23]. Ahmad et al. also suggested that the distal medial trochlea is totally non-load bearing, unlike the intercondylar notch, lateral trochlea and proximal medial trochlea where non-load-bearing areas are fairly limited [20]. Therefore, the distal medial trochlea appears to be the area of choice for osteochondral graft harvesting, bearing in mind the above-mentioned biomechanical considerations. Grafts from other areas may have to

be harvested, though, if a sizeable lesion has to be covered. Other factors that seem to influence the outcome are perpendicular graft insertion [9], delivering the graft flush with the joint surface and achieving adequate graft stability to avoid graft micromotion [29].

Our results are comparable with those reported in the literature regarding functional improvement and pain relief and suggest that this method is very effective in treating full-thickness chondral defects. Although no direct correlation between the size of the lesion and the functional outcome was found, one should bear in mind that increased lesion size raises concerns about graft availability and the ability to achieve stable graft fixation.

In conclusion, with this method, defects are resurfaced with osteochondral autografts, thus permitting joint surface covering with autologous hyaline cartilage as well as stable and safe graft incorporation. We believe that autologous osteochondral transplantation is a successful treatment option for focal osteochondral defects of the knee. It offers a very satisfactory functional outcome and does not compromise the patients' future options.

References

- [1] Prasad D, Learmonth D. Natural progression of osteo-chondral defect in the femoral condyle. *Knee* 2002;9:7–10.
- [2] Bobic V, Noble J. Articular cartilage To repair or not to repair? *J Bone Joint Surg Br* 2000;82-B:165–6.
- [3] Farnworth L. Osteochondral defects of the knee. *Orthopedics* 2000; 23(2):146–57.
- [4] Jaber FM. Osteochondritis dissecans of the weight-bearing surface of the medial femoral condyle in adults. *Knee* 2002;9:201–7.
- [5] Gross AE. Repair of cartilage defects in the knee. *J Knee Surg* 2002; 15(3):167–9.
- [6] Jacob RP, Franz T, Gautier E, Mainil-Varlet P. Autologous osteochondral grafting in the knee: indication, results and reflections. *Clin Orthop* 2002;401:170–84.
- [7] Hangody L, Feczko P, Bartha L, Bodo G, Kish G. Mosaicplasty for the treatment of articular defects of the knee and ankle. *Clin Orthop* 2001;391S:S328–36.
- [8] Hangody L, Fules P. Autologous osteochondral mosaicplasty for the treatment of full-thickness defects of weight-bearing joints. Ten years of experimental and clinical experience. *J Bone Joint Surg Am* 2003;85-A(Suppl. II):25–32.
- [9] Hangody L, Kish G, Karpati Z, Szerb I, Udvarhelyi I. Arthroscopic autogenous osteochondral mosaicplasty for the treatment of femoral condylar articular defects. A preliminary study. *Knee Surg Sports Traumatol Arthrosc* 1997;5:262–7.
- [10] Hangody L, Kish G, Karpati Z, Udvarhelyi I, Szigeti I, Bely M. Mosaicplasty for the treatment of articular cartilage defects: application in clinical practice. *Orthopedics* 1998;21(7):751–6.
- [11] Hangody L, Rathonyi GK, Duska Z, Vasarhelyi G, Fules P, Modis L. Autologous osteochondral mosaicplasty. Surgical technique. *J Bone Joint Surg Am* 2004;86-A(Suppl. I):65–72.
- [12] Agneskirchner JD, Brucker P, Burkart A, Imhoff AB. Large osteochondral defects of the femoral condyle: press-fit transplantation of the posterior femoral condyle (MEGA-OATS). *Knee Surg Sports Traumatol Arthrosc* 2002;10(3):160–8.
- [13] Irrgang JJ, Snyder-Mackler L, Wainner RS, Fu FH, Harner CD. Development of a patient-reported measure of function of the knee. *J Bone Joint Surg Am* 1998;80-A:1132–45.

- [14] Akizuki S, Yasukawa Y, Takizawa T. Does arthroscopic abrasion arthroplasty promote cartilage regeneration in oosteoarthritic knees with eburnation? A prospective study of high tibial osteotomy with abrasion arthroplasty versus high tibial osteotomy alone. *Arthroscopy* 1997;13(1):9–17.
- [15] Alleyne KR, Galloway MT. Management of osteochondral injuries of the knee. *Clin Sports Med* 2001;20(2):343–64.
- [16] Cain EL, Clancy WG. Treatment algorithm for osteochondral injuries of the knee. *Clin Sports Med* 2001;20(2):321–42.
- [17] Shahgaldi BF. Repair of large osteochondral defects: load-bearing and structural properties of osteochondral repair tissue. *Knee* 1998;5: 111–7.
- [18] Bentley G, Biant LC, Carrington RWJ, Akmal M, Goldberg A, Williams AM, et al. A prospective randomised comparison of autologous chondrocyte implantation versus mosaicplasty for osteochondral defects in the knee. *J Bone Joint Surg Br* 2003;85-B:223–30.
- [19] Horas U, Pelinkovic D, Herr G, Aigner T, Schnettler R. Autologous chondrocyte implantation and osteochondral cylinder transplantation in cartilage repair of the knee joint. A prospective comparative trial. *J Bone Joint Surg Am* 2003;85-A:185–92.
- [20] Outerbridge HK, Outerbridge AR, Outerbridge RE. The use of a lateral patellar autologous graft for the repair of large osteochondral defects on the knee. *J Bone Joint Surg Am* 1995;77-A:65–72.
- [21] Outerbridge HK, Outerbridge AR, Outerbridge RE, Smith DE. The use of lateral patellar autologous grafts for the repair of large osteochondral defects in the knee. *Acta Orthop Belg* 1999;65 (Suppl. 1):129–35.
- [22] Ahmad CS, Cohen ZA, Levine WN, Ateshian GA, Mow VC. Biomechanical and topographic considerations for autologous osteochondral grafting in the knee. *Am J Sports Med* 2001;29(2):201–6.
- [23] Bartz RL, Kamaric E, Noble PC, Lintner D, Bocell J. Topographic matching of selected donor and recipient sites for osteochondral autografting of the articular surface of the femoral condyles. *Am J Sports Med* 2001;29(2):207–12.
- [24] Marcacci M, Kon E, Zaffagnini S, Visani A. Use of autologous grafts for reconstruction of osteochondral defects of the knee. *Orthopedics* 1999;22(6):595–600.
- [25] Morelli M, Nagomori J, Miniachi A. Management of chondral injuries of the knee by osteochondral autogenous transfer (mosaicplasty). *J Knee Surg* 2002;15(3):185–90.
- [26] Menche DS, Vangsness CT Jr, Pitman M, Gross AE, Peterson L. The treatment of isolated articular cartilage lesions in the young individual. *Instr Course Lect* 1998;47:505–15.
- [27] Barber FA, Chow JCY. Arthroscopic osteochondral transplantation. *Arthroscopy* 2001;17(8):832–5.
- [28] Laprell H, Petersen W. Autologous osteochondral transplantation using diamond bone-cutting system (DBCS): 612 years' follow-up of 35 patients with osteochondral defects at the knee joint. *Arch Orthop Trauma Surg* 2001;121:248–53.
- [29] Pearse S, Hurtig MB, Clamette R, Karla M, Cowan B, Miniachi A. An investigation of 2 techniques for optimizing joint surface congruency using multiple cylindrical osteochondral autografts. *Arthroscopy* 2001;17(1):50–5.